USA HEALTH

Adopting Minimally Invasive & Keyhole Mentality in Skull Base Neurosurgery

Neurosurgical Society of Alabama, 2023

Jai Deep Thakur, MD

Assistant Professor, Neurosurgery

Director, Minimally Invasive and Cranial Neurosurgery
Director, Neurosurgery Education
University of South Alabama
Mobile, Alabama.

USA HEALTH

We have come a long way….

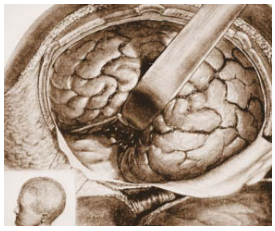

USA HEALTH

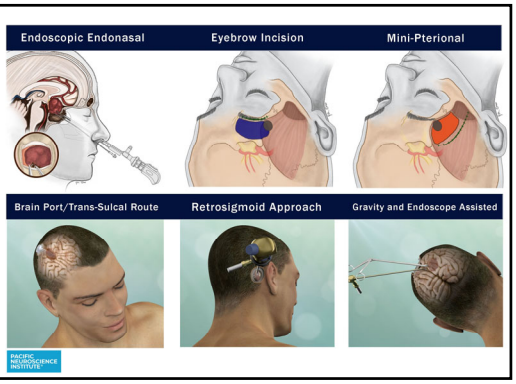

USA HEALTH

Reservations against the Eyebrow

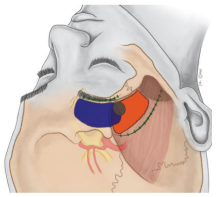

- Its only a Gimmick…
- Learning Curve
- "You just cant get that angle"
- Limited Exposure, Lesser tumor resection

USA HEALTH

Breaking down the Supraorbital Approach

- Modifications of the Supraorbital Approach
- Splitting the Fissure through an Eyebrow – The Holy Grail
- Following traditional Skull Base Rules
- Appreciating Blind Spots in this approach

USA HEALTH

Breaking down the Supraorbital Approach

- Modifications of the Supraorbital Approach
- Splitting the Fissure through an Eyebrow – The Holy Grail
- Following traditional Skull Base Rules
- Appreciating Blind Spots in this approach
- Complication handling

USA HEALTH

Breaking down the Supraorbital Approach

- Modifications of the Supraorbital Approach
- Splitting the Fissure through an Eyebrow – The Holy Grail
- Following traditional Skull Base Rules
- Appreciating Blind Spots in this approach
- Complication handling

Modifications of the Supraorbital Approach

USA MEDICAL CENTER

For Looking High – Supra Chiasmatic view

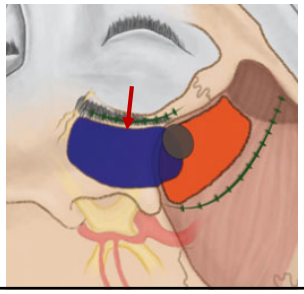

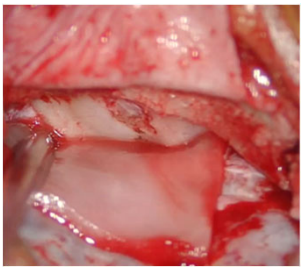

For Tumors Crossing Midline – How to Look Medial

USA MEDICAL CENTER

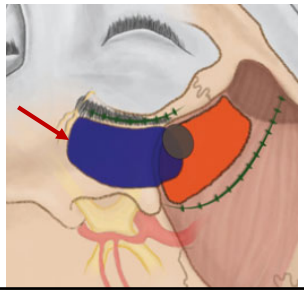

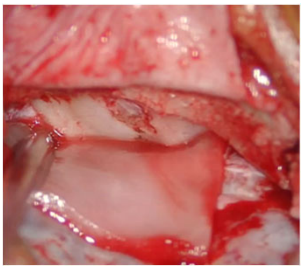

For Maximizing Lateral stretch in Anterior Skull Base tumors with some Upper Sphenoid Involvement

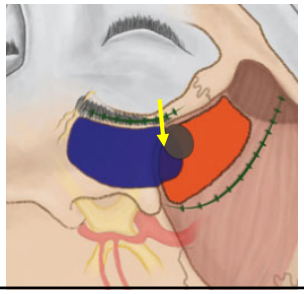

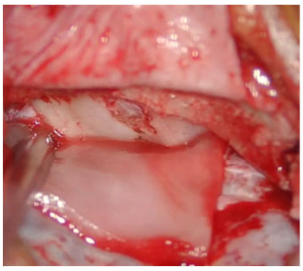

USA HEALTH

Splitting the Fissure through an EyeBrow – <u>The Holy Grail</u>

56 M

Complete R CN III palsy

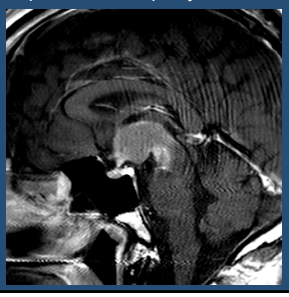

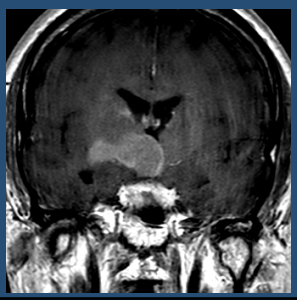

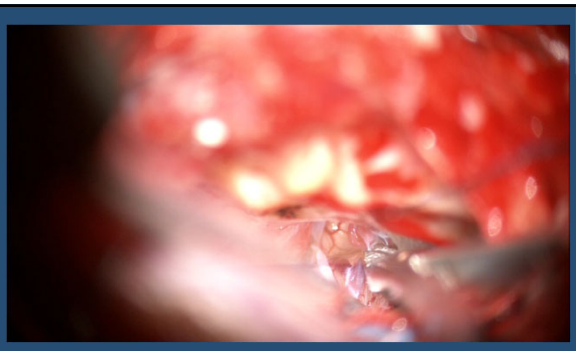

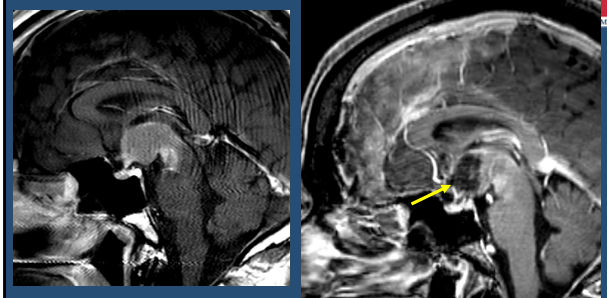

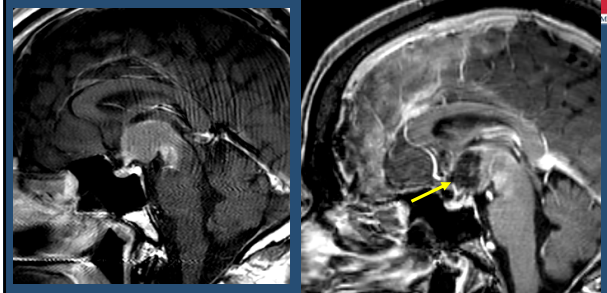

61 M

TIA
Seizures

Exam:
Intact

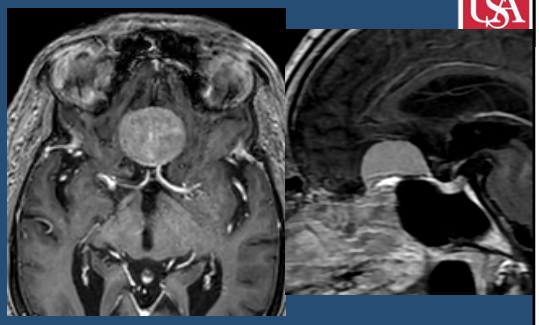

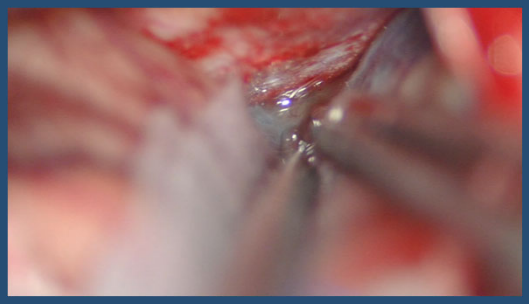

- Discharged Home on POD 2, Neuro Intact

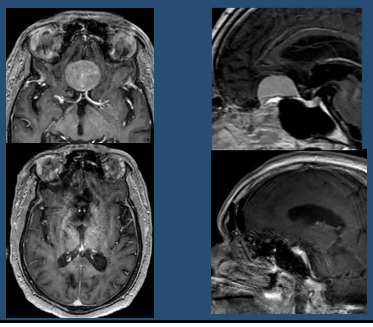

USA HEALTH

Following traditional Skull Base Rules & Still Innovating through Eyebrow

Bilateral Optic Canal Decompression

USA MEDICAL CENTER

- 56 F
- Progressive Vision Loss x 3 months
- Presented with acute vision decline Left > Right (20/100, 20/70)
- HTN, COPD, Obesity

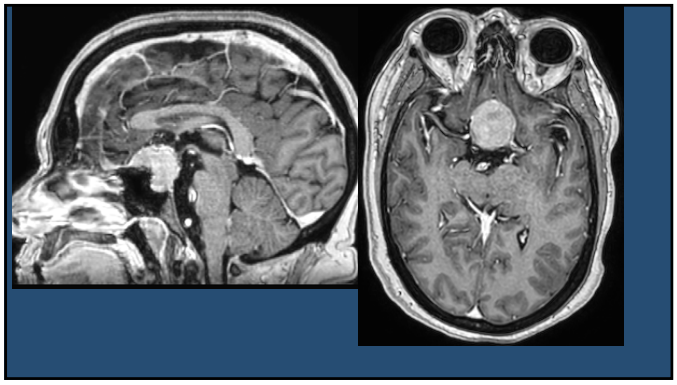

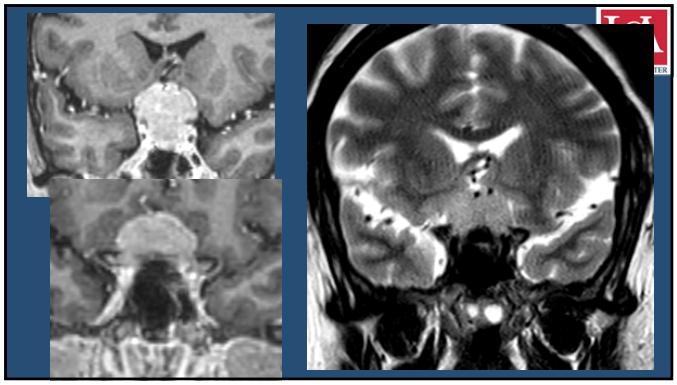

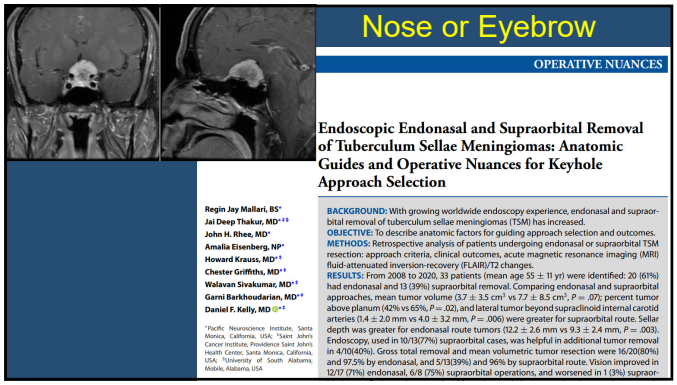

Nose or Eyebrow

OPERATIVE NUANCES

Endoscopic Endonasal and Supraorbital Removal of Tuberculum Sellae Meningiomas: Anatomic Guides and Operative Nuances for Keyhole Approach Selection

Regin Jay Mallari, BS[a]
Jai Deep Thakur, MD[a,b,§]
John H. Rhee, MD[a]
Amalia Eisenberg, NP[a]
Howard Krauss, MD[a,§]
Chester Griffiths, MD[a,§]
Walavan Sivakumar, MD[a,§]
Garni Barkhoudarian, MD[a,§]
Daniel F. Kelly, MD[a,§]

[a]Pacific Neuroscience Institute, Santa Monica, California, USA; [b]Saint John's Cancer Institute, Providence Saint John's Health Center, Santa Monica, California, USA; [§]University of South Alabama, Mobile, Alabama, USA

BACKGROUND: With growing worldwide endoscopy experience, endonasal and supraorbital removal of tuberculum sellae meningiomas (TSM) has increased.
OBJECTIVE: To describe anatomic factors for guiding approach selection and outcomes.
METHODS: Retrospective analysis of patients undergoing endonasal or supraorbital TSM resection: approach criteria, clinical outcomes, acute magnetic resonance imaging (MRI) fluid-attenuated inversion-recovery (FLAIR)/T2 changes.
RESULTS: From 2008 to 2020, 33 patients (mean age 55 ± 11 yr) were identified: 20 (61%) had endonasal and 13 (39%) supraorbital removal. Comparing endonasal and supraorbital approaches, mean tumor volume (3.7 ± 3.5 cm^3 vs 7.7 ± 8.5 cm^3, $P = .07$); percent tumor above planum (42% vs 65%, $P = .02$), and lateral tumor beyond supraclinoid internal carotid arteries (1.4 ± 2.0 mm vs 4.0 ± 3.2 mm, $P = .006$) were greater for supraorbital route. Sellar depth was greater for endonasal route tumors (12.2 ± 2.6 mm vs 9.3 ± 2.4 mm, $P = .003$). Endoscopy, used in 10/13(77%) supraorbital cases, was helpful in additional tumor removal in 4/10(40%). Gross total removal and mean volumetric tumor resection were 16/20(80%) and 97.5% by endonasal, and 5/13(39%) and 96% by supraorbital route. Vision improved in 12/17 (71%) endonasal, 6/8 (75%) supraorbital operations, and worsened in 1 (3%) supraor-

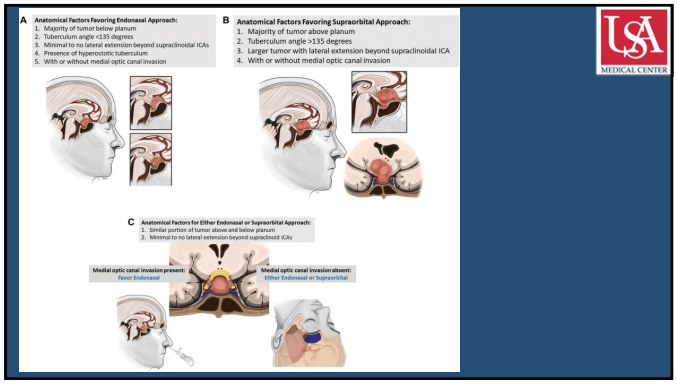

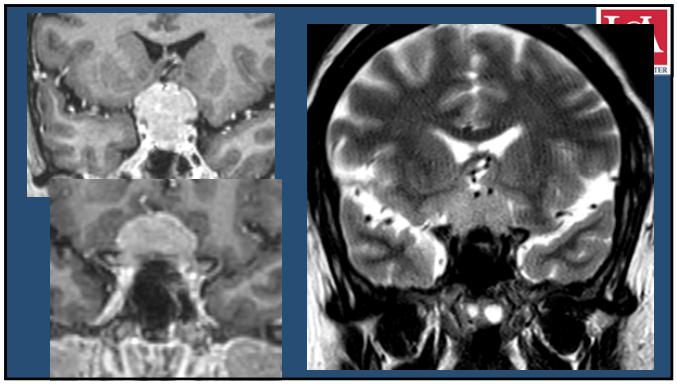

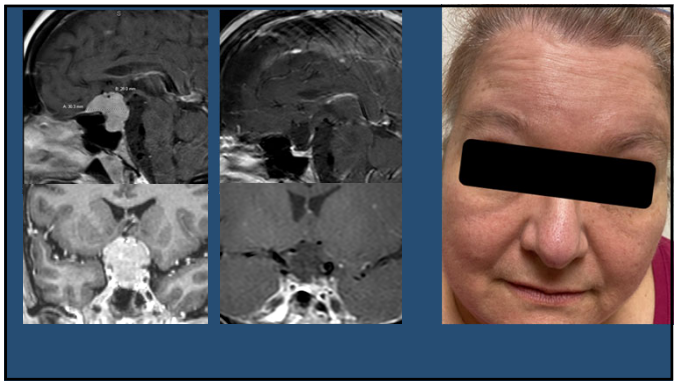

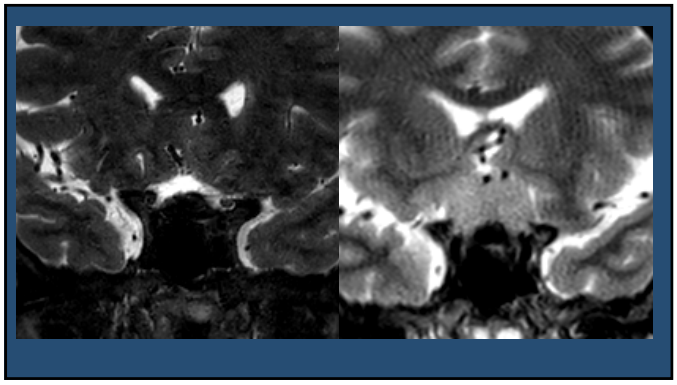

USA HEALTH

Micoscopic View

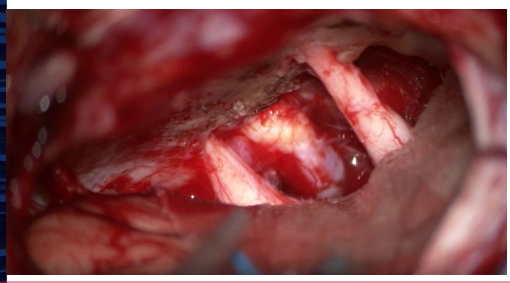

USA HEALTH

Endoscopic View

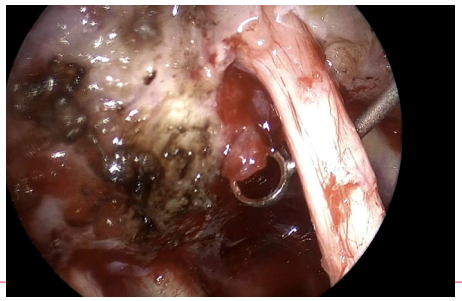

USA HEALTH

- 77 M, Worsening Confusion, Personality changes

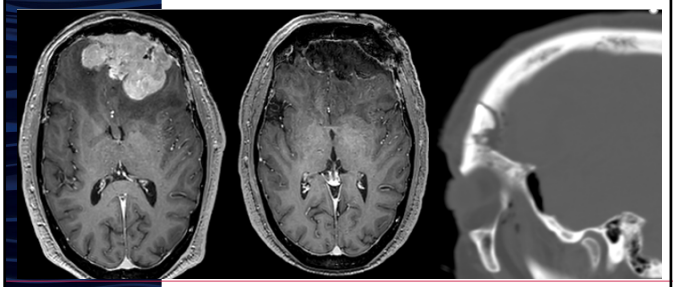

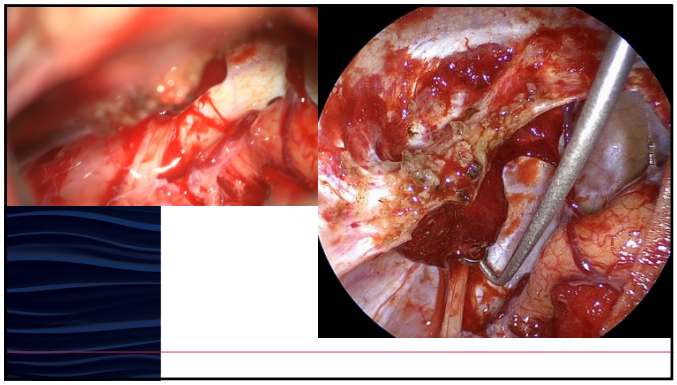

Orbital Encephalocele

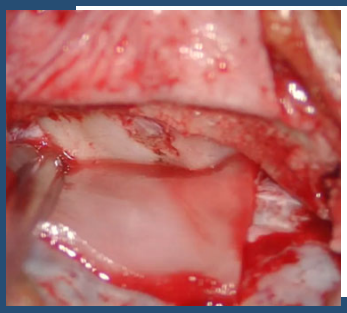

USA HEALTH

Endoscopic Dissection in Extended Retrosigmoid Approach

- 38 F with Right Hemifacial spasms
- MRI Giant Right side CP angle epidermoid tumor compressing brainstem and cranial nerves

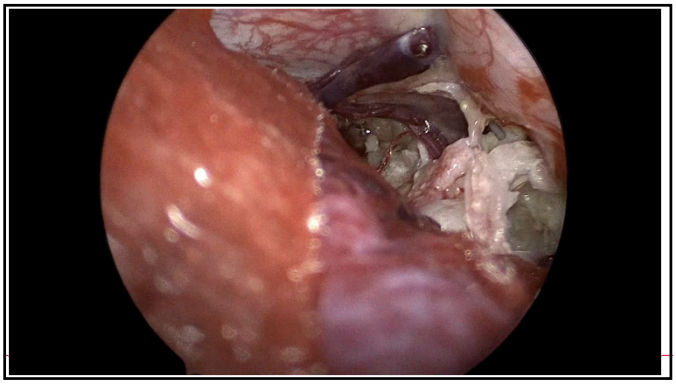

USA HEALTH

Trigeminal Neuralgia

Burr hole MVD

- Venous Compression

USA HEALTH

Video Case Examples

- Endoscopic Assist Trigeminal Neuralgia

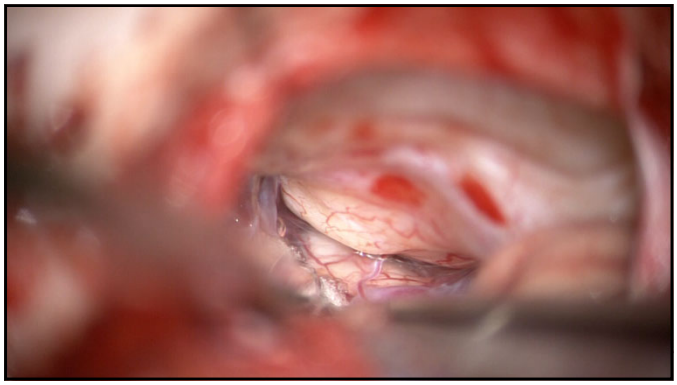

USA HEALTH

Video Case Examples

- Endoscopic Assist Hemifacial Spasm

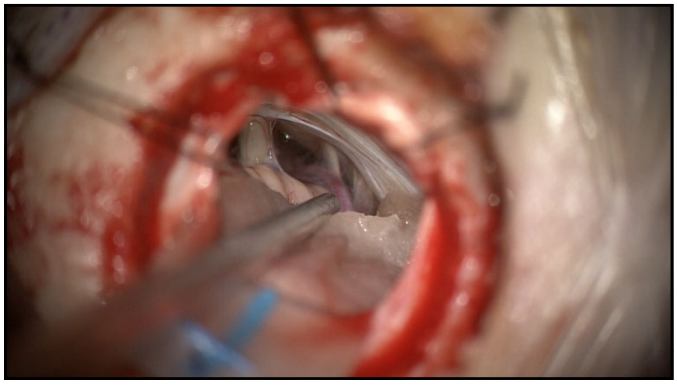

USA HEALTH

Why Minimally Invasive…

Our preliminary 2 year data….

USA HEALTH

Utilization of Keyhole Skull base Approaches in First 2 years of Practice: Outcomes, Complications, Post-discharge Narcotic Use and 30-day Readmissions

Daniel Cales, Luke Harris, John P Saway, Olivier Darbin, Danielle N Chason, Ursula Hummel, Anthony Martino, Jai Deep Thakur

University of South Alabama, Mobile, Alabama

Presented at North American Skull Base Society Meeting, Tampa, Florida. 2023

USA HEALTH

Retrospective study,

Consecutive patients undergoing MIS skullbase approaches from August 2020-August 2022 operated by single surgeon (JDT)

N = 141 brain tumor and skull base operations

Keyhole approaches were done on 60 patients

(Eyebrow Craniotomy: 12, 20%, Burr-hole Retrosigmoid 14, 23% and Endoscopic Endonasal 34, 57%).

USA HEALTH

Most common indications, median duration of surgery (min) and blood loss (ml) for the keyhole approaches were respectively,

1.Supraorbital: Meningioma (54%), 323 min, 50 ml

2.Burr-hole MVD Trigeminal Neuralgia (69%), 216 min, 50 ml

3.Endonasal Pituitary Adenoma (57%), 275 min, 75 ml.

Take back operation within 30 days was done in 1 patient for incomplete tumor resection.

Rigid retractors were not used in any cases

No case was converted to a conventional craniotomy.

USA HEALTH

Surgery related mortality or unexpected decline in KPS from baseline was noted in 0% cases

Median length of stay was 2 days.

Amongst the three routes, redo operations(first surgery done by another surgeon) were maximum in endonasal cohort while through eyebrow approaches, no redo surgery was attempted.

There were no strokes, CSF leaks, DVT's, PE or wound infection noted.

30-day readmission rates were 0%.

One patient required narcotics after discharge in their follow up

USA HEALTH

PLOS ONE

RESEARCH ARTICLE

Critical appraisal of minimally invasive keyhole surgery for intracranial meningioma in a large case series

Jal Deep Thakur[1,2,3], Regin Jay Mallari[1], Alex Corlin[1], Samantha Yawitz[1], Amalia Eisenberg[1], John Rhee[1,2], Walavan Sivakumar[1,2], Howard Krauss[1,2], Neil Martin[1,2], Chester Griffiths[1,4], Garni Barkhoudarian[1,2], Daniel F. Kelly[1,2]*

1 Pacific Neuroscience Institute, Providence Saint John's Health Center, Santa Monica, California, United States of America, **2** Saint John's Cancer Institute, Providence Saint John's Health Center, Santa Monica, California, United States of America, **3** University of South Alabama, Mobile, Alabama, United States of America

* dkelly@pacificneuro.org

Check for updates

OPEN ACCESS

Citation: Thakur JD, Mallari RJ, Corlin A, Yawitz S, Eisenberg A, Rhee J, et al. (2022) Critical appraisal of minimally invasive keyhole surgery for intracranial meningioma in a large case series. PLoS ONE 17(7): e0264053. https://doi.org/10.1371/journal.pone.0264053

Abstract

Background

Meningioma surgery has evolved over the last 20 years with increased use of minimally invasive approaches including the endoscopic endonasal route and endoscope-assisted and gravity-assisted transcranial approaches. As the "keyhole" concept remains controversial, we present detailed outcomes in a cohort series.

USA HEALTH

PLOS ONE

Minimally invasive meningioma surgery

Table 2. Meningioma characteristics, resection rates & surgical parameters for 213 keyhole operations.

	Endonasal (n = 74)	Supraorbital (n = 73)	Mini-pterional (n = 20)	Retromastoid (n = 38)	Suboccipital (n = 4)	Transfalcine (n = 4)	Total (n = 213)
GTR	17 (23%)	34 (46.6%)	10 (50%)	19 (50%)	2 (50%)	3 (75%)	85 (40%)
GTR/NTR	22 (29.7%)	54 (74%)	14 (70%)	28 (73.7%)	3 (75%)	4 (100%)	125 (58.7%)
Redo Surgery (had prior surgery)	24 (32.4%)	16 (21.9%)	3 (15%)	3 (7.9%)	1 (25%)	0	47 (22.1%)
Invasion to CS/MC/Orbit /ITF	40 (54%)	15 (21%)	10 (50%)	9 (24%)	0	0	74 (35%)
Median Skull Base Compartments Occupied	2	2	2	2	1	1	2
Mean Max Tumor Diameter (mm)	29.1 ± 13.2	28.5 ± 13.0	29.7 ± 14.1	32.1 ± 13.5	26.5 ± 12.5	40.0 ± 21.2	29.7 ± 13.4
Use of Endoscopy	74 (100%)	54/73 (74%)	5/20 (25%)	21/38 (55%)	3/4 (75%)	4/4 (100%)	161/213 (76%)
New/Worsened FLAIR/T2 Changes (mean diam, mm)	2/74	11/73	4/20	18/48	1/4	0/4	36/213
	2.7%	15.1%	20.0%	37.5%	25%	0	(16.9%)
	(2.5mm)	(6.9 mm)	(9.5 mm)	(8.1 mm)	(11 mm)	(NA)	(7.67 mm)
Persistent FLAIR Changes at 3 months or more postop	1/74 (1.4%)	2/73 (2.7%)	2/20 (10%)	6/48 (12.5%)	0	0	11/213 (5.2%)
Median LOS	3	3	2	2	3	2	3

USA HEALTH

Conclusion

- Keyhole Approaches substantially improve the postoperative recovery with relatively good outcomes, shorter hospital stay, lower readmissions and negligible narcotic use
- Patient Selection
- Learning Curve



USA HEALTH

Thank you

Jai D Thakur

Assistant Professor of Neurosurgery
Director of Minimally Invasive Cranial & Skull Base Neurosurgery;
Director of Neurosurgery Education
University of South Alabama

Email: jthakur@health.southalabama.edu
Cell: (408) 228 2211